

How to Diagnose and Treat Back Pain in the Horse

A. Kent Allen, DVM; Susan Johns, DVM;
Sallie S. Hyman, VMD, Diplomate ACVIM; Margaret D. Sislak, DVM;
Stephanie Davis, DVM; and Joseph Amory, DVM

Authors' address: Virginia Equine Imaging, 2716 Landmark School Road, The Plains, Virginia 20198; e-mail: vaequine@aol.com (Allen). © 2010 AAEP.

1. Introduction

Back pain results in decreased range of motion and limited flexibility of the thoracolumbar spine, and it leads to performance issues in the equine athlete. Ancillary therapeutics and alternative therapies are often administered to patients with back pain. Such treatments without an accurate diagnosis fail to provide sufficient pain management in the affected horses.¹ It is critical to obtain a complete performance history and assess each horse's back through detailed palpation and visual inspection at rest and in motion. Specialized imaging techniques such as nuclear scintigraphy with digital radiography are able to diagnose and direct management of equine back disorders. The treatment of affected horses aims to alleviate discomfort and muscle spasm to make the horse as comfortable as possible to perform while promoting muscle function and strength. Some of the most effective therapies performed in our clinic for successful management of back pain include extracorporeal shockwave therapy (ESWT), mesotherapy, injections with corticosteroids, and systemic tiludronate therapy. At our practice, these non-invasive to minimally invasive medical treatments have been

favorable for return to athletic use. This manuscript discusses multiple therapeutic options for thoracolumbar inflammation after diagnosis by moving, clinical, and imaging evaluation.

2. Materials and Methods

Back Pathology

Back pain in the performance horse is bifurcated between soft-tissue and/or bone pathology. Often bone and soft-tissue structures are affected in concert; however, characterizing individual abnormalities allows for accurate treatment selection. The thoracolumbar vertebral column is susceptible to spinous process osteoarthritis (Fig. 1), dorsal articular process osteoarthritis (Fig. 1), and spondylosis deformans (Fig. 2). Soft-tissue pathology leading to thoracolumbar pain includes epaxial muscle inflammation and supraspinous ligament desmitis.

Clinical Examination

Patients frequently present with a history of decreased performance and avoidance behavior. Poor jumping technique, bucking, and resistance to being saddled often correlate with thoracolumbar pain.²

NOTES

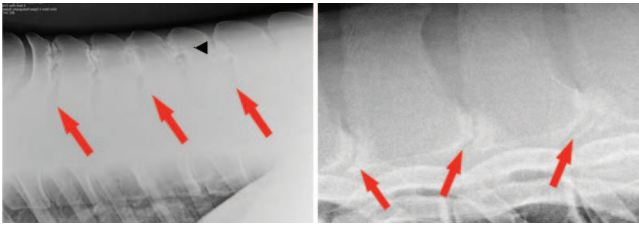


Fig. 1. Left lateral digital radiographs showing severe mid-caudal thoracic spinous processes impingement (left) and caudal thoracic dorsal articular process sclerosis (right).

During the moving evaluation, horses are frequently rigid in the back, resistant to moving forward, and buck or “bunny hop” when weight is applied over the saddle region. On physical examination, many horses are painful to palpation and/or have poor top-line musculature. For this reason, all horses presenting for lameness/performance evaluation should undergo a standing visual inspection. Patients are evaluated for symmetric or asymmetric muscle atrophy as well as axial and abaxial vertebral misalignment. Horses should undergo palpation of the dorsal spinous processes of the entire thoracolumbar spine in a systematic manner. The fingertips should press down directly over the dorsal spinous processes only to determine the degree of sensitivity from the vertebrae alone. Evaluation of the bone separately from the epaxial musculature allows the clinician to help differentiate between bone and soft-tissue sensitivity. Making the distinction between bone and soft-tissue inflammation is the first step in directing an appropriate treatment protocol. A thorough moving evaluation should follow the physical inspection, with the horse viewed on a straight line and in both directions of a circle over a firm surface. It is also informative to see the horse under saddle as well. Moving the horse with weight applied over the saddle region is essential in confirming back pain as a performance issue. In addition, at our clinic, a weighted surcingle^a is applied (Fig. 3) with 50 lb dead weight, and the horse is observed for signs of discomfort while being girthed and when moving in both directions of

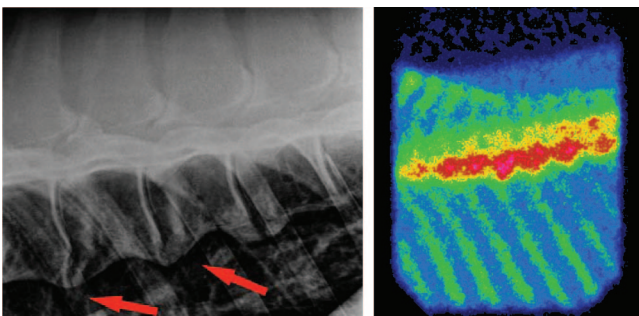


Fig. 2. Radiographic image of spondylosis with a corresponding nuclear scintigraphic image of the same area.



Fig. 3. Moving examination with a 50-lb weighted surcingle to evaluate gait and behavioral change with a simulated rider.

a lunge circle. The weighted surcingle system allows the treating clinician to view the patient before and after weight placement, without the effect of the rider influencing the horse's natural way of going. Additionally, if there is a history of bucking, a proper evaluation may be made without the risk of putting a rider on a dangerous horse.

Imaging of the Back

After a clinical impression of back pain is developed, diagnostic tools must be used to determine the precise pathology. Nuclear scintigraphy and digital radiography are invaluable for providing differential diagnoses and directing management of equine back disorders. These two modalities alone are beneficial; however, scintigraphy and radiography used together provide a more accurate, clinically relevant diagnosis.

Digital radiographic (DR) imaging of the back should include the entire thoracolumbar spine from the level of the scapula to the superimposition of the tuber coxae. The spinous processes, dorsal articular processes, and vertebral bodies on a true lateral-lateral image should be included in the evaluation (Fig. 4). Obliquity and equipment limitations may preclude appropriate image acquisition. Multiple views of the same region at different technique settings may be required to achieve diagnostic-quality radiographs. In a practice setting with DR and




Fig. 4. Positioning for lateral thoracolumbar radiography and oblique nuclear scintigraphic imaging of the thoracolumbar spine.




Fig. 5. Lateral oblique scintigraphic images of the mid-thoracic vertebral region; cranial is to the left. Pronounced increased radiopharmaceutical uptake (red arrows) of the apices of the spinous processes and DAP (blue arrows) is evident.

high-output X-ray equipment, it is technically feasible to gather quality diagnostic views that include all relevant anatomy in the same radiograph.¹ In our clinic, these images are achieved using a Direct Digital Radiology Unit^b with a 500-mA Mobile X-Ray Pushcart.^c

Nuclear scintigraphy provides a metabolic assessment of the osseous structures of the axial skeleton. Additionally, scintigraphy allows for visualization and improved localization of active bone inflammation on lateral, oblique, and dorsal images. At our practice, a gamma camera^d (Figs. 4 and 5) is used 2–4 h after IV injection of 200-mCi MDP-^{99m} technetium. Images are acquired at 100,000 counts during the bone phase of the isotope in the standing horse. Findings indicative of bony inflammation are anatomically localized, graded, and compared with digital radiographs before patient treatment.

With scintigraphic evidence of bone inflammation, digital radiographs are taken to grade the severity of the clinically relevant findings. Vertebral bodies are examined for remodeling, asymmetry, and indications of destabilization. The dorsal articular processes (DAP) are evaluated (mild, moderate, or severe) for abnormal size, shape, and opacity. Spinous processes are investigated for interspinous narrowing/overriding, sclerosis, and lysis. Determination of both the severity and location of pathology is essential for accurate treatment type and placement.

Spinous process impingement (SPI) is the most common abnormality in the thoracolumbar spine. Lesions are most often observed from T10 to T18; however, SPI occurs from T10 to L6.¹ In a recent study of 644 horses with back pain, 571 (89%) showed radiographic evidence of SPI with and without additional vertebral lesions.³ Additionally, 77 (12%) horses showed abnormalities of the thoracolumbar DAP, with the majority (47/77; 61%) occurring at concurrent sites of SPI. These data indicate DAP osteoarthritis as the second most common pathologic abnormality observed in horses with back pain.³ Abnormal DAPs are most frequently observed from T15 to L1. Most lesions are bilateral, and typically, multiple sites are affected; radiogra-

phy and scintigraphy used together are best for identification of clinically significant lesions.^{3,4} Spondylosis occurs infrequently, and the condition seems more prevalent in mares. In these cases, radiography is superior to scintigraphy for lesion identification.⁵ The clinical significance of spondylosis is not known; however, the lesions are often progressive and most likely secondary to intervertebral destabilization. Some horses are able to perform satisfactorily with this lesion.

Patients with clinical evidence of back pain without radiographic and scintigraphic indications of bone pathology most likely suffer a soft-tissue injury. The horse often suffers muscle pain; however, ligamentous damage should be ruled out. If warranted, sonographic investigation of the area(s) in question should be performed.

Treatments

After diagnosis by digital radiography and nuclear scintigraphy, an appropriate treatment protocol can be developed. The treatments available are: ESWT, mesotherapy, interspinous processes injection, ultrasound-guided injection of the DAP, and systemic Tiludronate therapy. These treatments aim to alleviate discomfort and muscle spasm to make the horse as comfortable as possible to perform while promoting muscle function and strength. Simply resting a horse with back pathology is not recommended for most clinical cases. This may lead to muscle loss and further complicate and slow the horse's return to work.

ESWT is a useful non-invasive treatment modality for pain associated with the osseous structures in the horse.⁶ This therapy should be used on patients with SPI and/or DAP osteoarthritis. It is important to note that placement of the probe in relation to the target structure is critical for appropriate therapy when using ESWT.⁷ The sonic pulse that the probe emits has a relatively small focal area, which makes it imperative to identify the exact anatomical location of the lesions being treated. It is common at our practice to use the highest available energy setting on a high energy focused shockwave machine^{e,f} with a depth setting based on the specific pathology identified with imaging. SPI is treated with a 35-mm probe placed axially and abaxially over the entire length of the thoracolumbar spinous processes (Fig. 6). An 80-mm probe is used to reach the DAP, with the probe placed abaxially over the left and right sides of the patient's vertebral column in large, deeply muscled horses (in the region of the lumbar vertebrae; L1–L6). At our clinic, 1,000–2,000 pulses are applied during each therapy session. After these treatments, clients are advised to give patients 2 days off and then gradually return to a regular level of work over 3–5 days. Timing of serial treatments is based on the horse's response to therapy and are performed anywhere from 4 to 12 mo apart.



Fig. 6. ESWT of the back showing correct probe placement for spinous process and DAP treatment.

Severe DAP/SPI osteoarthritis/osteoarthritis is sometimes treated with injectable corticosteroids in addition to ESWT. The horse is tranquilized so that the head hangs down, separating the spinous process/articular process interface to facilitate needle placement. Articular processes identified by imaging are treated by ultrasound-guided injection using a 20-gauge, 3.5-in spinal needle with short- and long-acting corticosteroids. Impinged spinous processes are also injected with a combination of short- and long-acting corticosteroids but with a 20- or 22-gauge, 1.5-in needle. The interspinous space is identified by palpation, and the needle is directed vertically between the apices. After either treatment, we recommend 3–5 days off followed by a gradual return to work over 7 days.

In addition to ESWT, our clinic commonly will treat a horse concurrently with mesotherapy to alleviate soft-tissue inflammation (Fig. 7). Mesotherapy is an effective technique to control pain by blocking sensory-pain fibers that pass through the skin in the epaxial region.¹ A solution consisting of 30 ml mepivacaine,^a 3 mg flumethasone,^h and 12 ml traumeel^l is diluted in Lactated Ringer's Solution for a total 120-ml volume. Twenty-seven-gauge intradermal needles are used with a multi-injector, and the medication is injected intradermally to make a row of dime-sized blebs. Three rows are placed within the left and right subcuticular space over the epaxial musculature. The first row is delivered 4 cm off midline, and all additional rows are 4 cm apart. Treatment with mesotherapy is applicable when immediate soft-tissue pain relief is needed. After treatment, we recommend 3–5 days of rest and



Fig. 7. Mesotherapy application (left) and resulting proper anatomic placement (right).

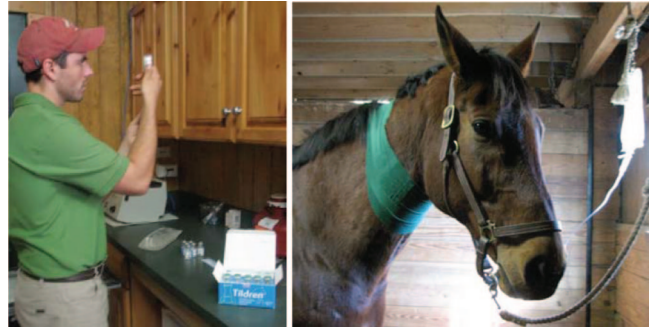


Fig. 8. Systemic tiludronate therapy.

then gradually returning the horse to regular work over 7 days. Treatment is repeated as indicated on recheck examinations and/or after complaints of back pain are reported by the client.

Tiludronate therapy is recommended for patients with severe bone inflammation and osteolysis noted on correlated radiography and scintigraphy (Fig. 8). This treatment has proven efficacious when given to horses with both back pain and radiographic evidence of osseous pathology.⁸ This treatment is offered at our hospital for treating pathology of the spine and is strongly recommended for moderate to severe spondylosis and osteoarthritis/osteoarthritis. A 1.0-mg/kg dose of tiludronate is given in a 1-l bag of 0.9% NaCl over 1 h after a 2.2-mg/kg dose of flunixin meglumine. Maximum effect of tiludronate is achieved 6–8 wk after treatment and lasts for 4 mo or more.⁸

Rehabilitation and Exercise Management

After treatment, rehabilitation protocol is patient-dependent. For example, severely painful horses will often need time exercising without carrying the weight of a rider and tack. Horses with mild back pain can quickly return to regular exercise after a 1- to 3-day rest period. Clients are advised to have saddle fit evaluated by a reputable professional. When returning to work, we recommend alterations to the horse's warm-up routine. Increasing the amount of walking exercise and working the horse at the canter before starting into trot work helps many horses with back pain. Nevertheless, in almost all of our patients, we recommend keeping the horses in some level of work. In our experience, horses that are rested for long periods of time lose valuable epaxial muscle tone, and their back pain persists.

3. Results and Discussion

Response to treatment is determined by recheck examinations and client perceptions of patient performance after therapy. Repeat examinations are conducted by the treating veterinarian and include a physical exam, back palpation, and moving evaluation. Improved top-line musculature, decreased pain on palpation of the spine, and increased sup-

pleness and flexibility during lunging with and without a weighted surcingle all indicate a positive response to treatment. The client's subjective opinion of treatment efficacy and length of response is valued and used in determining long-term pain management.

To evaluate the outcome of our diagnosis-guided therapies of the thoracolumbar spine, all back pain cases with follow-up physical and moving examinations were reviewed. At our clinic, it is common to radiograph the back. From January 2008 to December 2009, 115 horses had radiographs taken of the thoracolumbar spine. Seventy-four of those cases were available for follow-up, and 89% (66) of the horses had a positive outcome to treatment. The length of treatment efficacy for horses that improved was determined, and 30% (22) of horses improved for 2–4 mo, 28% (21) of horses improved for 4–6 mo, and 31% (23) of horses improved for greater than 6 mo. Eleven percent (8) of horses were considered treatment failures in that no improvement was noted after treatment or length of improvement was less than 2 mo in duration. The 41 horses that were not included in these percentages were cases being referred. Those horses went back to their referring veterinarian and were not evaluated at our clinic post-treatment.

Thoracolumbar pain occurs commonly in performance horses and is often difficult to treat.¹ The most effective therapies available require identification and diagnosis of specific axial skeletal pathology. Imaging modalities such as nuclear scintigraphy and digital radiography are essential for lesion identification but are most effective when incorporated with a thorough physical and moving examination. Clinically normal horses can have mild increased radiopharmaceutical uptake (IRU) and mild radiographic abnormalities with a negative clinical examination.^{9–12} Additionally, radiography and scintigraphy individually vary in sensitivity and specificity for individual pathologic conditions of the axial skeleton. Use of both modalities in clinically affected horses is ideal for assessing the combined structural pathology and metabolic activity of vertebral lesions.^{1,13} Lesions are, therefore, considered clinically relevant in symptomatic horses with both radiographic and scintigraphic evidence of thoracolumbar pathology.⁸

References and Footnotes

1. Denoix JM, Dyson SJ. Thoracolumbar spine. In: Ross MW, Dyson SJ, eds. *Diagnosis and management of lameness in the horse*. St. Louis, MO: Saunders, 2003;512.
2. Walmsley JP, Pettersson H, Winberg F, et al. Impingement of the dorsal spinous processes in two hundred and fifteen horses: case selection, surgical technique, and results. *Equine Vet J* 2002;34:23–28.
3. Girodroux M, Dyson S, Murray R. Osteoarthritis of the thoracolumbar synovial intervertebral articulations: clinical and radiographic features in 77 horses with poor performance and back pain. *Equine Vet J* 2009;41:130–138.
4. Gillen A, Dyson S, Murray R. Nuclear scintigraphic assessment of the thoracolumbar synovial intervertebral articulations. *Equine Vet J* 2009;41:534–540.
5. Meehan L, Dyson S, Murray R. Radiographic and scintigraphic evaluation of spondylosis in the equine thoracolumbar spine: a retrospective study. *Equine Vet J* 2009;41:800–807.
6. McCarroll GD, McClure S. Extracorporeal shockwave therapy for treatment of osteoarthritis of the tarsometatarsal and distal intertarsal joints of the horse, in *Proceedings*. 46th Annual American Association of Equine Practitioners Convention 2000;200–202.
7. Coombs R, Schaden W, Zhou S. *Musculoskeletal shockwave therapy*. London, UK: Greenwich Medical Media Ltd, 2000;4.
8. Coudry V, Thibaud D, Riccio B, et al. Efficacy of tiludronate in the treatment of horses with signs of pain associated with osteoarthritic lesions of the thoracolumbar vertebral column. *Am J Vet Res* 2007;68:329–337.
9. Erichsen C, Eksell P, Widstrom C, et al. Scintigraphic evaluation of the thoracic spine in the asymptomatic riding horse. *Vet Radiol Ultrasound* 2003;44:330–338.
10. Erichsen C, Eksell P, Roethlisberger Holm K, et al. Relationship between scintigraphic and radiographic evaluations of the spinous processes in the thoracolumbar spine in riding horses without clinical signs of back problems. *Equine Vet J* 2004;36:458–465.
11. Jeffcott LB. Radiographic examination of the equine vertebral column. *Vet Radiol* 1979;20:135–139.
12. Jeffcott LB. Radiographic features of the normal equine thoracolumbar spine. *Vet Radiol* 1979;20:140–147.
13. Johns S, Allen AK, Tyrell LA. How to obtain digital radiographs of the thoracolumbar spine in the standing horse, in *Proceedings*. 54th Annual American Association of Equine Practitioners Convention 2008;455–458.

^aThe Astride, Eponaire LLC, Loxahatchee, FL 33470.

^bSound-Eklin Mark V, Eklin Medical Systems Inc., Santa Clara, CA 95054.

^cSedecal (SM-HF Vet Mobile X-Ray Unit), Toshiba, Japan.

^dEquistand, Diagnostic Services Inc., Middlesex, NJ 08846.

^eVersatron, Pulsevet, Alpharetta, GA 30022.

^fEquitron, Pulsevet, Alpharetta, GA 30022.

^gCarbocaine-V, Pharmacia & Upjohn Company, Division of Pfizer Inc., New York, NY 10017.

^hFlucort, Fort Dodge Animal Health, Fort Dodge, IA 50501.

ⁱTraumeel, Heel Inc., Albuquerque, NM 87123.